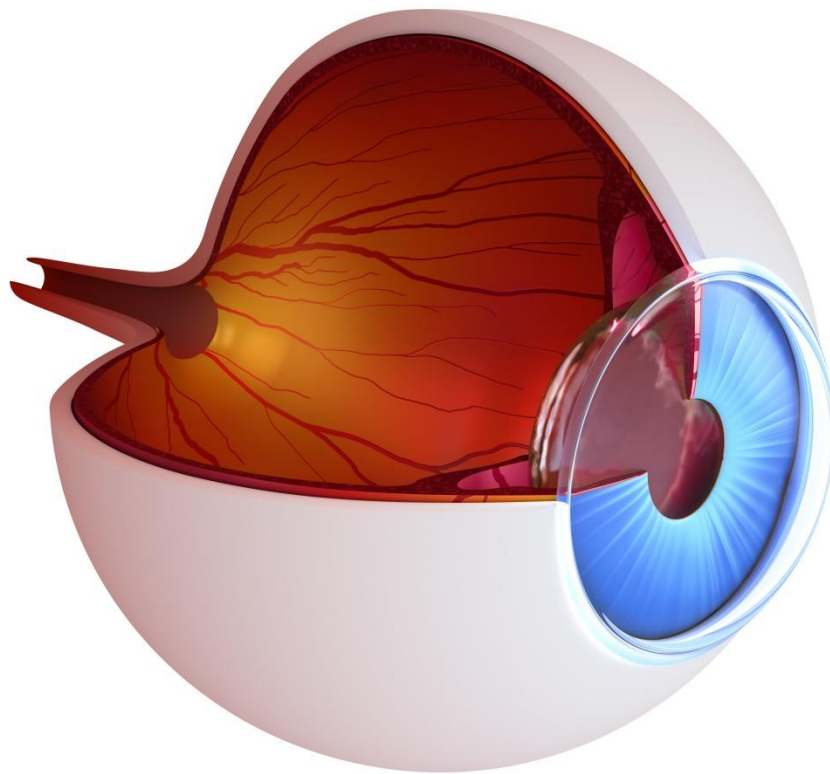


# Visual Loss Secondary to Cosmetic Filler Injection



Seriousness of complication		Frequency of complication	
Major complication		x	Very rare
<b>Title</b>	Visual Loss Secondary to Cosmetic Filler Injection		
<b>Author</b>	Dr Lee Walker, Dr Martyn King		
<b>Date</b>	October 2017		
<b>Version</b>	2.5		

# Visual Loss Secondary to Cosmetic Filler Injection

## Definition:

Any impairment or loss of vision (temporary or permanent) secondary to central retinal or retinal branch artery occlusion occurring as a direct consequence of percutaneous injection for aesthetic treatment<sup>1</sup>.

## Introduction:

Blindness after facial injection is extremely rare and was first reported by von Bahr over 50 years ago after scalp injection of a hydrocortisone suspension to treat alopecia<sup>2</sup>. The first cases after aesthetic filler treatments were reported in the 1980s (four cases) and rose to at least 16 reported cases in the between 2000-2010, presumably related to the increase in the number of treatments being performed<sup>1</sup>.

Depending on which artery is occluded, vision loss can be classified into six subtypes<sup>3,4,5</sup>:

1. Ophthalmic artery occlusion (OAO)
2. Generalized posterior ciliary artery occlusion with relative central retinal artery sparing (PCAO)
3. Central retinal artery occlusion (CRAO)
4. Branch retinal artery occlusion (BRAO)
5. Anterior ischaemic optic neuropathy (AION)
6. Posterior ischaemic optic neuropathy (PION)

There are also four subtypes of periocular complications associated with blindness following cosmetic filler injection<sup>6</sup>:

Type I – Blindness without ophthalmoplegia (paralysis or weakness of ocular muscles) and ptosis

Type II – Blindness with ptosis but without ophthalmoplegia

Type III – Blindness with ophthalmoplegia but without ptosis

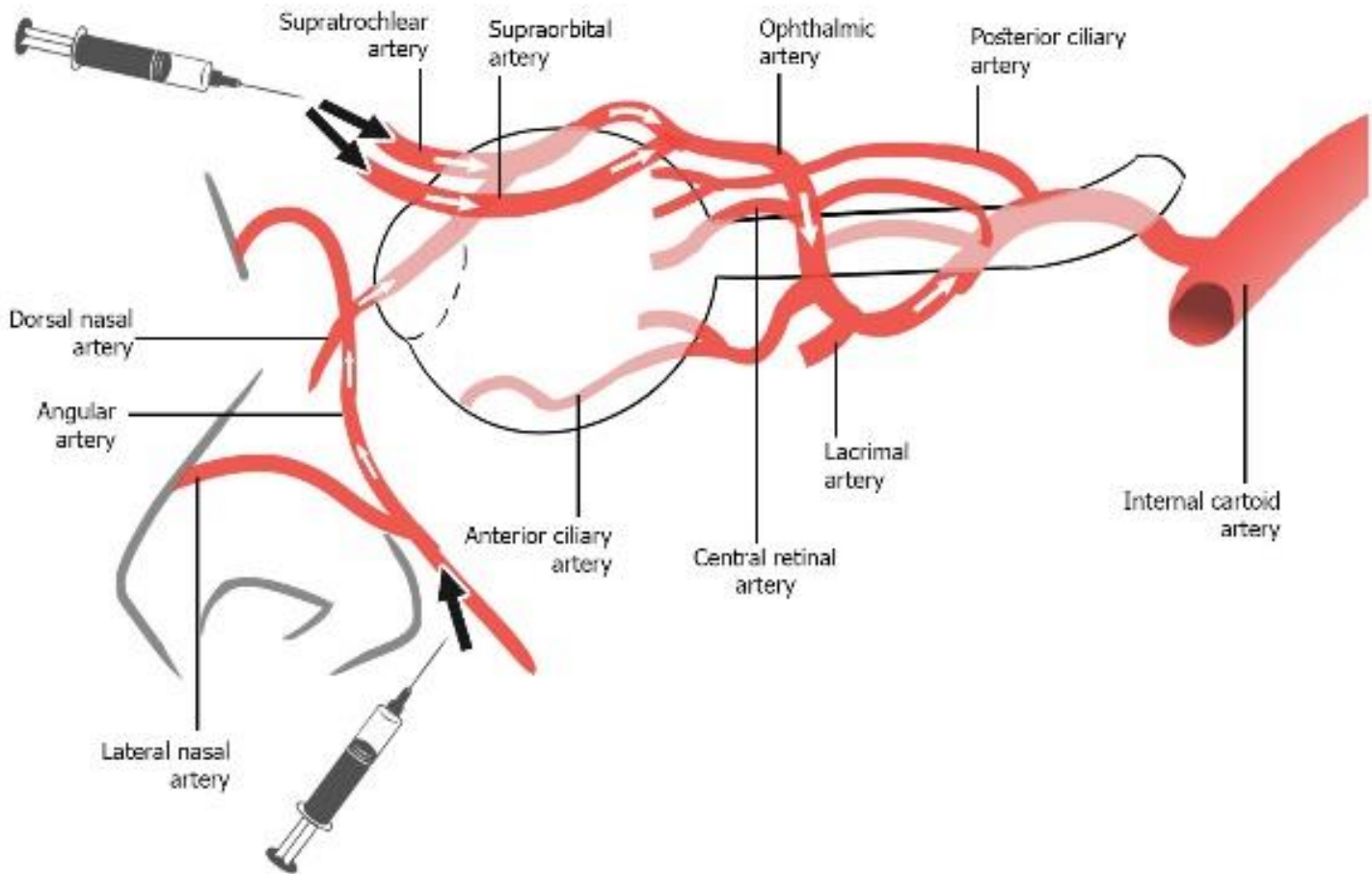
Type IV – Blindness with ophthalmoplegia and ptosis

Based on previously reported case studies, improvement of visual acuity in patients with vascular occlusion after filler injection is extremely rare. By contrast, periocular symptoms such as ptosis and ophthalmoplegia recovered dramatically<sup>6</sup>.

## Mechanism:

Terminal branches of the ophthalmic artery, namely the supraorbital and supratrochlear, supply the medial forehead and anastomoses between these vessels and the terminal branches of the angular artery are well documented<sup>7</sup>. Similarly, anastomoses with the superficial temporal arteries and the orbit has also been demonstrated<sup>8</sup>. Injection of filler material into one of these vessels may lead to retrograde flow to beyond the point of the origin of the ophthalmic artery and when pressure from the plunger is released, systolic pressure drives the product forward and to enter the ophthalmic artery or central retinal artery resulting in visual loss.

The requirements for blindness to occur include the retrograde and subsequent anterograde passage of material, injection pressure exceeding systolic pressure and sufficient amount of material within the lumen of the vessel. Findings indicate that the average entire volume of the supratrochlear artery from the glabella to the orbital apex is 0.085ml (range 0.04-0.12ml)<sup>9</sup> and injection volume should not exceed this volume in critical injection points.



**Incidence:**

Globally, at least 98 cases of visual loss after aesthetic facial injection have been reported prior to 2015<sup>1,10,11,12</sup>. A review of the world literature by Belezany<sup>12</sup> identified 98 cases of vision change. High risk areas were glabella (38.8%), nasal region (25.5%), nasolabial fold (13.3%), and forehead (12.2%). Autologous fat was responsible for most of the complications (47.9%) followed by hyaluronic acid (23.5%)<sup>12</sup> and the outcome was worse in cases when autologous fat had been injected<sup>5,10</sup>.

In 2012, the UK reported its first case (after injection to the temple with Poly-L-Lactic Acid, the first report with this product)<sup>13</sup>. In 2013, the first two cases of bilateral blindness were reported (calcium hydroxyapatite to the nose and hyaluronic acid to the glabella, which also led to cerebral infarction)<sup>11</sup>. The exact incidence of this devastating adverse event remains to be determined due to the heterogeneity of data<sup>7</sup>.

Due to the seriousness of this complication, significant visual loss should be explained to the patient as a possible rare complication as part of the consent process<sup>11</sup>.

**Signs and symptoms:**

- Pain (Ocular, facial, headache or a combination)
- Nausea
- Vision loss
- Paralysis or weakness of ocular muscles
- Ptosis
- Posterior displacement of the eye
- Strabismus (misalignment of the eyes when looking at an object)
- Corneal oedema
- Pupillary abnormality
- Iris atrophy
- Anterior chamber inflammation

- Phthisis bulbi (shrunken, non-functional eye)
- Livedo reticularis (a mottled, reticulated vascular pattern of the skin)

Visual loss following embolization of dermal filler typically occurs within seconds of injection<sup>7</sup> although visual loss has been reported 7 hours post-treatment in the case of a posterior ciliary artery occlusion<sup>14</sup>. Complete loss of vision is the normal presentation although there may be visual field defects. Visual loss is often accompanied by sudden onset of severe pain (ocular, facial, headache or any combination) although central retinal and retinal branch artery occlusions may present without ocular pain. Other symptoms include ophthalmoplegia (paralysis or weakness of ocular muscles), ptosis, enophthalmos (posterior displacement of the eye) and horizontal strabismus (abnormal alignment of the eyes). These symptoms accompany blindness due to disturbed flow to the superior and inferior branches which supply the extraocular muscles<sup>6</sup>.

Many cases with visual loss and periocular symptoms also subsequently developed enophthalmos and surgery could be considered in patients demonstrating greater than 2mm descent within 6 weeks of the injury<sup>15</sup>.

Other symptoms and signs include<sup>7</sup> corneal oedema, anterior chamber inflammation, nausea, headache, pupillary abnormality, iris atrophy, phthisis bulbi and livedo reticularis.

Cerebral infarction can accompany retinal artery occlusion and therefore signs and symptoms of this may also be present such as aphasia or even contralateral hemiparesis. Central nervous complications were seen in 23.5%<sup>12</sup> to 39%<sup>5</sup> of cases where vision was affected.

An MRI scan should be performed in all patients who suffer visual loss or ocular pain as a result of filler injections<sup>10</sup>.

## Areas of caution:

Injections into the nose and glabella form the vast majority of reported cases of blindness<sup>7</sup> although moderate risk sites included the nasolabial folds, forehead, periocular region, temple and cheek. Uncommon sites were the eyelid, lips and chin. Due to the complex vascularity of the face, any region of the face has the potential to cause this complication<sup>4</sup>.

## Minimising the risk:

The key preventative strategies are listed below<sup>6</sup>:

1. Know the location and depth of facial vessels and the common variations<sup>7</sup>. Injectors should understand the appropriate depth and plane of injection at different sites.
2. Inject slowly and with minimal pressure<sup>1,4,11</sup>.
3. Inject in small increments<sup>1,7</sup> so that any filler injected into the artery can be flushed peripherally before the next incremental injection. This prevents a column of filler traveling retrograde and subsequently anterograde. No more than 0.1 mL of filler should be injected with each increment.
4. Move the needle tip while injecting<sup>4</sup>, so as not to deliver a large deposit in one location.
5. Always aspirate before injection<sup>1,4,7</sup>. This recommendation is controversial as it may not be possible to get flashback into a syringe through fine needles with thick gels. In addition, the small size and collapsibility of facial vessels limit the efficacy.
6. Use a small-diameter needle<sup>1,7</sup>. A smaller needle necessitates slower injection and is less likely to occlude the vessel. If a sharp needle is being used then a perpendicular injection directly in contact with the bone is recommended; injecting into a deeper plane may avoid vessels<sup>7</sup>.
7. Smaller syringes<sup>4</sup> are preferred to larger ones as a large syringe may make it more challenging to control the volume and

increases the probability of injecting a larger bolus.

8. Consider using a cannula (minimum size 25G), as they are less likely to pierce a blood vessel<sup>1,7</sup>. Some authors recommend use of the cannula in the medial cheek, tear trough, and nasolabial fold.
9. Use extreme caution when injecting a patient who has undergone trauma or a previous surgical procedure in the area<sup>4</sup>.
10. Ensure that you are adequately trained, using an appropriate product and are competent in the area in which you are treating as well as competent of the management of complications.
11. A technique to possibly prevent embolism of filler is digital compression of the inferior-medial orbital rim and the side of the nose<sup>7</sup> whilst injecting.

Sometimes the ophthalmic artery does not arise normally from the internal carotid artery, but from the middle meningeal artery, which originates from the external carotid artery. Furthermore, the zygomatic-orbital artery raised from the superficial temporal artery has an anastomosis with branches of the ophthalmic artery, and may be a retrograde arterial embolic route<sup>14</sup>. Facial anatomy can be diverse and the facial artery originated from a single arterial trunk in 86% of specimens and branching patterns were only symmetrical in 53% of cases<sup>16</sup>. In conclusion, there is no absolute safe area of the face to inject<sup>1</sup>.

### **Treatment of blindness after facial injection:**

Once the retinal artery has been occluded there is a window of 60-90 minutes before blindness is irreversible<sup>7</sup>. It is advisable to transfer the patient to the nearest specialist eye hospital via blue light ambulance as quickly as possible<sup>4</sup>. Transfer to a non-specialist emergency department may lead to inordinate delay and worse outcome<sup>7</sup>. Ensure that you know which your closest specialist eye department is and contact the on-call team as soon as possible to inform them of the situation. Give medical staff as much

information as possible about the product, area and volume of injection.

Although there is no generally agreed treatment regimen<sup>17</sup>, there are actions that may help. Prado<sup>18</sup> suggests a 6 step therapy protocol with a 'blindness safety kit' that may be used in a clinical setting then continued into hospital. The protocol was adapted from Lazzeri et al<sup>1</sup>.

### **Treatment Algorithm for Ocular Pain and Blindness After Facial Fillers**

Indications for treatment are sudden onset ocular pain and/or loss of vision. The goal is to quickly reduce the intraocular pressure to allow for the emboli to dislodge downstream and improve retinal perfusion<sup>1</sup>. Treatment must start within 90 minutes.

- Stop treatment immediately.
- Place patient in supine position<sup>7</sup>.
- Call 999 and prepare to transfer patient to hospital setting as soon as possible.

**Do not let any of the below delay referral to a specialist eye hospital.**

#### **Reduce Intraocular Pressure<sup>7</sup>**

Administer Timolol<sup>4,7</sup> 0.5% 1-2 drops in the affected eye only. This beta-adrenergic antagonist will aim to reduce intraocular pressure by reducing aqueous humor production.

The patient should be encouraged to 'rebreathe' in a paper bag. The aim is to increase CO<sub>2</sub> levels within the blood which will cause retinal arteries to vasodilate and could help dislodge blockage. An alternative to rebreathing through a paper bag is the inhalation of carbogen (95% oxygen, 5% carbon dioxide)<sup>4</sup>.

Oral acetazolamide<sup>4,7,14</sup> may be considered although intravenous administration in hospital is likely to be of greater benefit.

Give the patient 300 mg of aspirin to prevent blood clotting<sup>14</sup>.

### **Dislodge the embolus to a more peripheral position**

Massage the globe with repeated increasing pressure. Prolonged ocular massage attempts to dislodge emboli by rapidly changing intraocular pressure<sup>4</sup> thereby changing the pressure and flow in the retinal arteries. Increasing the intraocular pressure also causes a reflexive dilation of the retinal arterioles and dropping it suddenly increases the volume of flow significantly.

Ocular massage is performed with the patient looking straight ahead with eyes closed. Gentle pressure is applied over the sclera with a finger, indenting the globe by a few millimetres and then releasing at a frequency of 2-3 times a second<sup>19</sup>. This should be continued until advised otherwise by staff at the eye hospital. Commonly, firm ocular massage is advised for several seconds and repeated only a few times. The alternative advice originates from 2 case studies where embolised retinal arteries were directly visualised during the massage process. This showed that even when the emboli were dislodged, more would occlude the vessel when massage stopped. Prolonged high frequency massage (up to 3 hours) had a better clearing effect<sup>19</sup>.

### **Administer Hyaluronidase**

If hyaluronic acid has been used, administer hyaluronidase to the treatment area according to ACE Group guideline "The Use of Hyaluronidase in Aesthetic Practice". Retrobulbar injection of hyaluronidase has been advocated by many plastic surgeons as emergency treatment, however an evaluation by Zhu et al<sup>3</sup> failed to show any improvement in visual loss following 1500-3000 units of hyaluronidase injected into the retrobulbar space in 4 patients. Consensus from Ophthalmologists when consulted on the topic of retrobulbar hyaluronidase injections by aesthetic practitioners is that it is a technically

difficult procedure even to a competent Ophthalmological Surgeon and the scope for causing more harm means the risks outweigh any benefit. However, Chestnut<sup>20</sup> recently reported in Dermatologic Surgery full restoration of vision after blindness was reported in a patient receiving hyaluronic acid fillers in the midface. Vision was restored following three retrobulbar hyaluronidase injections and aspirin. A total of 750 units were administered, 450 units as retrobulbar injections and 300 units to surround the supraorbital and infraorbital foramina. Retrobulbar injections should only be considered by practitioners competent in this procedure in a specialist eye unit.

Injection of hyaluronidase into the supratrochlear or supraorbital arteries to reach the embolus seems a more sensible approach.

The use of hyaluronidase has been shown to be ineffective at recanalizing the retinal artery occlusion or improving the visual outcome after 4 hours after onset of blindness<sup>3</sup>.

### **Specialist Treatment**

Once the patient has been transferred to the hospital setting, the aim is to further reduce intraocular pressure, remove/reverse central retinal ischaemia and increase blood flow to the retina.

- Injection of 500mg IV Acetazolamide. This should increase retinal blood flow and reduce intraocular pressure.
- Consider the use Enoxaparin subcutaneously or IV Heparin for anticoagulation<sup>7</sup>. If the patient is having signs or symptoms of cerebral infarction, defer this step until a Neurologist has assessed the patient.
- Intravenous infusion of mannitol 20% (100ml over 30 minutes)<sup>4,7</sup>.
- Consider injection of hyaluronidase via the transorbital approach into the more prominent and tortuous postseptal ophthalmic artery<sup>21</sup>.

**Other supportive therapies include<sup>18</sup>:**

- Anterior chamber paracentesis<sup>7,11</sup> to immediately lower intraocular pressure.
- Steroid administration<sup>7</sup>, intravenous dexamethasone<sup>4,14</sup>.
- Judicious use of antibiotics for suspected infection<sup>7</sup>.
- Hyperbaric oxygen may salvage vulnerable retinal damage<sup>7,11,14</sup>. Practitioners should familiarise themselves with their nearest hyperbaric oxygen chamber.
- Intravenous prostaglandin E1<sup>4</sup> to increase blood flow to the retina and decrease activation of thrombocytes and neutrophils.

## References

1. Lazzeri D, Agonstini T, Figus M, Nardi M, Pantaloni M, Lazzeri S. Blindness following cosmetic injections of the face. *Plastic Reconstructive Surgery*, 2012 April; 129(4):995-1012
2. von Bahr G. Multiple embolisms in the fundus of an eye after an injection in the scalp. *Acta Ophthalmol (Copenh.)* 1963;41:85–91
3. Zhu GZ, Sun ZS, Liao WX, Cai B, Chen CL, Zheng HH, Zeng L, Luo SK. Efficacy of Retrobulbar Hyaluronidase Injection for Vision Loss Resulting from Hyaluronic Acid Filler Embolization. *Aesthetic Surg J* 2017,1-11
4. Szantyr A, Orski M, Marchewka I, Orska M, Zapala J. Ocular Complications Following Autologous Fat Injections Into Facial Area: Case Report of a Recovery from Visual loss After Ophthalmic Artery Occlusion and a Review of the Literature. *Aesthetic Plast Surg.* 2017 Jun; 41(3) 580-584
5. Park KH, Kim YK, Woo SJ. Iatrogenic Occlusion of the Ophthalmic Artery After Cosmetic Facial Filler Injections. *JAMA Ophthalmol.* 2014;132(6):714-723
6. Yujin M, Sangjun Y, et al. The Classification and Prognosis of Periocular Complications Related to Blindness following Cosmetic Filler Injection. *Plastic and Recon surg:* July 2017;140(1):61-64
7. Loh KTD, Chua JJ. Prevention and management of vision loss relating to facial filler injections. *Singapore Med J* 2016. 57(8):438-443
8. Tansatit T1, Moon HJ, Apinuntrum P, Phetudom T. Verification of Embolic Channel Causing Blindness Following Filler Injection. *Aesthetic Plast Surg.* 2015 Feb;39(1):154-61
9. Khan TT, Colon-Acevedo B, Mettu P, DeLorenzi C, Woodward JA. An Anatomical Analysis of the Supratrochlear Artery: Considerations in Facial Filler Injections and Preventing Vision Loss. *Aesthetic Surg J.* 2017 Feb;37(2):203-208
10. Woo SJ, Park SW, Park KH, Huh JW, Jung C, Kwon OK. Iatrogenic retinal artery occlusion caused by cosmetic facial filler injections. *American Journal of Ophthalmology*, 2012 Oct; 154(4):653-662
11. Carle MV, Roe R, Novack R, Boyer DS. Cosmetic Facial Fillers and Severe Vision Loss. *JAMA Ophthalmol.* Published online March 06, 2014. doi:10.1001/jamaophthalmol.2014.498
12. Belezany K, Carruthers JDA, Humphrey S, Jones DJ. Avoiding and Treating Blindness From Fillers: A Review of the World Literature. *Dermatologic Surg* 2015;41:1097-1117
13. Townshend, A. Blindness after facial injection. *Journal of Clinical and Aesthetic Dermatology.* Published online December 2016. doi: 763416-dec-2016/60
14. Hu XZ, Hu JY. Posterior Ciliary Artery Occlusion Caused by Hyaluronic Acid Injections Into the Forehead. *Medicine*;95(11): March 2016
15. Hazani R, Yaremchuk MJ. Correction of posttraumatic enophthalmos. *Arch Plast Surg.* 2012;39:11–17
16. Lohn JW, Penn JW, Norton J, Butler PE. The course and variation of the facial artery and vein: implications for facial transplantation and facial surgery. *Ann Plast Surg.* 2011 Aug;67(2):184-8
17. Fraser SG, Adams W. Interventions for acute non-arteritic central retinal artery occlusion. *Cochrane Database Syst Rev.* 2009 Jan 21;(1):CD001989. doi: 0.1002/14651858.CD001989.pub2.
18. Prado G, Rodriguez-Feliz J. Ocular Pain and Impending Blindness During Facial Cosmetic Injections: Is Your Office Prepared? *Aesth Plast surg* 2017;41:199-203
19. Baker DL. Gentle, prolonged ocular massage can restore vision after retinal artery occlusion. *Ocular Surgery News U.S. Edition*, July 1, 2004
20. Chestnut C. Restoration of Visual Loss With Retrobulbar Hyaluronidase Injection After Hyaluronic Acid Filler. *Dermatol Surg.* 2017;0:1-3
21. Tansatit T1, Apinuntrum P, Phetudom T. An anatomic basis for treatment of retinal artery occlusions caused by hyaluronic acid injections: a cadaveric study. *Aesthetic Plast Surg.* 2014 Dec;38(6):1131-7



# Visual Loss Secondary to Cosmetic Filler Injection

The ACE Group have produced a series of evidence based and peer reviewed guidelines to help practitioners prevent and manage complications that can occur in aesthetic practice. These guidelines are not intended to replace clinical judgement and it is important the practitioner makes the correct diagnosis and works within their scope of competency. Some complications may require prescription medicines to help in their management and if the practitioner is not familiar with the medication, the patient should be appropriately referred. Informing the patient's General Practitioner is considered good medical practice and patient consent should be sought. It may be appropriate to involve the General Practitioner or other Specialist for shared care management when the treating practitioner is not able or lacks experience to manage the complication themselves. Practitioners have a duty of care and are accountable to their professional bodies and must act honestly, ethically and professionally.

## **Author**

Dr Lee Walker  
Dr Martyn King

## **Expert Group**

Dr Martyn King (Chair)  
Emma Davies RN NIP (Vice Chair)  
Sharon King RN NIP  
Dr Cormac Convery  
Dr Lee Walker

## **Consensus Group**

Constance Campion RN NIP  
Helena Collier RN NIP  
Dr Ben Coyle  
Dr Harryono Judodihardjo  
Dr Sam Robson  
Mr Taimur Shoab