

Facial topography of the injection areas for dermal fillers, and associated risks

Topografia facial das áreas de injeção de preenchedores e seus riscos

Authors:

Bhertha M. Tamura¹

¹ Dermatology Coordinator, Ambulatório Médico de Especialidades Barradas—São Paulo (SP), Brazil

Correspondence:

Dr. Bhertha M. Tamura
Rua Ituxi, 58 / apt. 603
Cep: 04055-020—São Paulo—SP, Brazil
E-mail: bhertha.tamura@yahoo.com.br /
bhertha.tamura@uol.com.br

Received on: 10 June 2013

Approved on: 15 July 2013

The present study was carried out at a private practice—São Paulo (SP), Brazil.

Financial support: None
Conflict of interest: None

ABSTRACT

Introduction: Filling techniques are an important procedure in modern therapeutic approaches to rejuvenation, and are currently in wide use.

Objective: To assist the practice of dermal filling procedures and reduce associated risks.

Method: Division of the face into 22 regions in which filling procedures are indicated, providing detailed description of the nervous and vascular structures of each.

Results: This didactic, practical, and detailed new division of the regions of the face highlights the possible risks related to anatomical features, thereby facilitating implementation, and reducing the risks and complications of filling techniques, such as the widely-feared amaurosis and tissue necrosis.

Conclusion: Only a thorough knowledge of facial anatomy enables the safe realization of dermal filling procedures.

Keywords: anatomy; risk zone; face.

RESUMO

Introdução: As técnicas de preenchimento constituem importante procedimento na moderna abordagem terapêutica do rejuvenescimento, sendo largamente utilizadas na atualidade.

Objetivo: Auxiliar a prática dos preenchimentos e diminuir seus riscos.

Método: Divisão da face em 22 regiões nas quais se indicam preenchimentos, com descrição detalhada das estruturas nervosas e vasculares de cada uma.

Resultado: Essa nova divisão didática, prática e pormenorizada das regiões da face, evidenciando os possíveis riscos ligados às características anatômicas de cada região facilita a execução e diminui riscos e complicações das técnicas de preenchimento, tais como a tão temida amaurose e necroses teciduais.

Conclusão: Só o conhecimento profundo da anatomia facial permite a realização de preenchimentos com segurança.

Palavras-chave: anatomia; zona de risco; face.

INTRODUCTION

The classification of the face according to risk zones, when studying dermatologic surgery, can serve as a reference tool and assist in the new therapeutic rejuvenation practice of cutaneous facial filling. However, having only a generic, basic knowledge of anatomy might be insufficient and gives rise to doubts during the performance of this technique—especially regarding the areas and depth of injections.¹⁻⁴ The injection of fillers in the superficial layers of the skin, excepting the glabellar region, presents minimal risk. However, filling techniques have evolved and in most current cases the procedures are performed in the hypodermis and even in the supraperiosteal plane. In an attempt to better guide dermatologists and minimize complications, the present study is aimed at proposing a new didactic and practical classification of facial regions for implementing filling techniques, highlighting possible risks linked to specific anatomical features.⁵⁻¹²

METHOD

As opposed to what has been described in the literature, the face was divided into 21 regions, with a view to adjusting the areas where fillings are performed: frontal (1), temporal (2), glabellar (3), eyebrow (4), upper eyelid (5), lower eyelid (6), nasociliary (7), nasojugal sulcus (8), eyelid lateral sulcus (9), nasal (10), malar (11), zygomatic (12), canine fossa (13), nasolabial sulcus (14), upper lip (15), lower lip (16), cheek (17), preauricular (18), labiomental sulcus (19), mentonian (20), posterior mandibular region (21), (anterior border of the masseter up to the angle of the jaw) and anterior mandibular region (between the melolabial fold and the anterior border of the masseter). The boundaries of these areas are shown in figure 1, followed by a detailed description of each region.¹³⁻¹⁸

FRONTAL REGION (1)

This area was delimited excluding the glabella. An imaginary line was drawn above the eyebrow, originating in the mid pupillary regions and bilaterally reaching the hairline. It is important to note that when located on osseous structures, this area of skin, subcutaneous tissue, and muscle is relatively thin. Any filler injected in this region might result in lumps or a visibly linear texture. It is important to bear in mind that the aponeurosis of the frontal muscle—or that of the galea—begins at the level of the scalp’s border.

TEMPORAL REGION (2)

The temporal region has the mid pupillary line as a border in its cranial portion; the hair implantation line, in its lateral portion; a line passing above the eyebrows that extends and outlines the lateral orbital border; finally closing with the zygomatic arch as a reference for the lower border. This region presents risks due to the presence of the superficial temporal artery, in addition to the nerve and veins. The injection of dermal fillers in the dermis of this area would present low risk, however, the subcutaneous injection of substances may cause not only lesions in the veins (with hematoma or ecchymosis formation), but also in the nerve, if the procedure were to be performed in an intempestive manner. The structure that calls for the most attention is the temporal artery; its channeling and the intravascular injection of fillers can lead to tissue necrosis and embolization of the product, and may even cause amaurosis, as occurs with several other arterial branches in the upper region of the face due to the presence of anastomoses between superficial and deep arteries. In general, cutaneous fillings in this area can be carried out in the dermis, subcutaneous, or supraperiosteal planes. When a choice is made to fill the subcutaneous area, it is important to pay attention to the demarcation of the visible

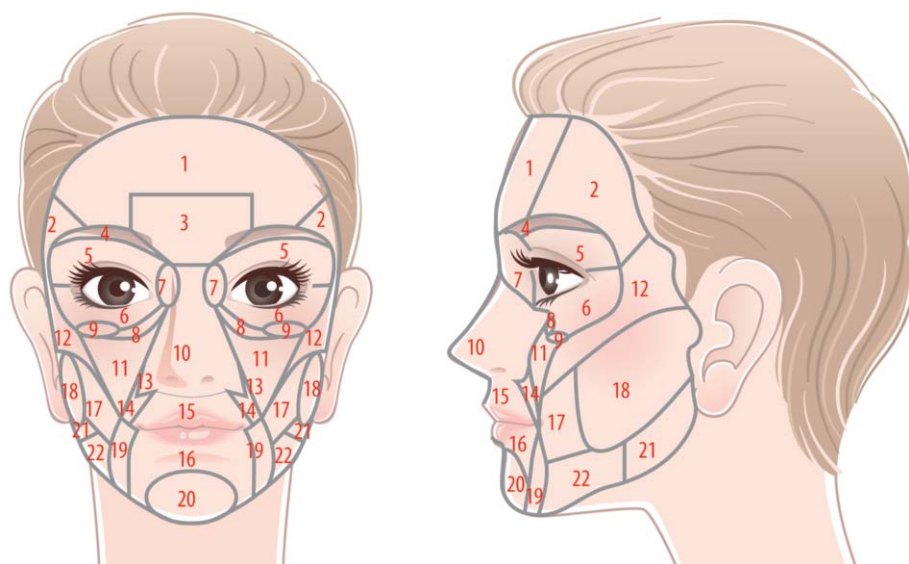


FIGURE 1: frontal (1), temporal (2), glabellar (3), eyebrow (4), upper eyelid (5), lower eyelid (6), nasociliary (7), nasojugal sulcus (8), eyelid lateral sulcus (9), nasal (10), malar (11), zygomatic (12), canine fossa (13), nasolabial sulcus (14), upper lip (15), lower lip (16), cheek (17), preauricular (18), labiomental sulcus (19), mentonian (20), posterior mandibular region (21) = (anterior border of the masseter up until the angle of the jaw) and anterior mandibular region (between the melolabial fold and the anterior border of the masseter).

venous tree as well as of the arteries. When the injection is carried out in supraperiosteal planes, the risks of vascular channelling are lower, especially in the temporal fossa.

GLABELLAR AND EYEBROW REGIONS (3 AND 4)

The limits of the glabellar region are: the superior area of the nasal dorsum and the medial portion of the eyebrow (inferiorly), and the line that links the 1.5 cm segments of the mid pupillary line in the cranial direction (superiorly). The eyebrow region corresponds to the region with hair, going along the eyebrow up until its lateral portion, where there is the possibility for cutaneous filling. The supraorbital artery (which arises through the supraorbital foramen and originates from the internal carotid artery) and the supratrochlear artery (a branch of the facial artery) must also be considered. Currently, it is no longer advisable to inject products for filling wrinkles or scars in the glabellar region, due to the possibility of arterial embolism with consequent amaurosis. In this region—as in the temporal region—there are arteries that can be anastomosed and have their blood flow directed to terminal arteries, such as the ophthalmic and retinal arteries. The embolization of these vessels can lead to immediate and irreversible amaurosis, which can even be bilateral. In addition to taking care not to channel the arteries, it is important to pay attention and avoid deep injections in the area of the supraorbital and supratrochlear foramina, preventing the ischemia of the structures that arise in this site. In addition to the treatment of the medial and lateral portions of the eyebrow, there is also the possibility that fillers can be injected in the medial portion (nasociliary region) for the treatment of epicanthus, bearing in mind that this area is not devoid of risks.

UPPER EYELID (5)

The description of this area is especially important due to the fact that injections of fillers have been carried out throughout its upper portion (just below the eyebrow) aimed at correcting the “skeletonized gaze”. More specifically, through attempting to also correct the deficiency of the fat pad in that region and/or the loss of support that characterizes a “deep” gaze. The upper eyelid artery, in continuity with the angular artery, irrigates this area. There is little local supporting tissue, with the presence of skin and of the orbicularis oculi muscle, and below, the fat pads and the lacrimal gland, with the possibility of vascular accident.

LOWER EYELID, NASOJUGAL SULCUS (LACRIMAL GROOVE) AND NASOCILIARY REGION (6, 7 AND 8)

There is indication for the correction of this region after a negative aesthetic result following the removal of fat pads in eyelid surgery, loss of support of the entire lower eyelid's orbital rim, or exacerbation of the medial, lower and/or lateral palpebromalar sulcus due to family characteristics. There is a close relationship between the lower eyelid area and the nasojugal sulcus (medial portion that goes along the medial inferior orbital rim) and the nasociliary region. It is important to pay attention to the anatomy of these regions and to consider them jointly.

Part of the angular artery, the inferior palpebral artery and the infraorbital artery (which unites with the dorsal nasal artery) are located underneath these areas, giving rise to the risk of tissue necrosis or embolism. When carrying out filling injections in these areas, the planes that bear lower risk of complications would be the muscular and the supraperiosteal—for the vessels are located under the skin and over the orbicularis oculi muscle. The procedure must be performed with delicacy and precision, either with cannulas or needles.

LATERAL PALPEBRAL SULCUS (9)

It is located in the lateral portion of the lower eyelid, over the lateral inferior orbital rim. In this area, attention must be paid to the temporomaxillary vein, which lies under the skin (often visible when the skin is translucent) and crossing almost perpendicularly the infraorbital rim, between its medial region and lateral third. Its prior identification prevents complications such as echymoses and hematomas.

NASAL REGION (10)

Some details must be taken into account when patients undergo nasal sculpture:

The dorsal nasal artery lies in the subcutaneous tissue, on a plane under the skin and over the dorsal nasal muscle, and can have branches that anastomose with the infraorbital and angular arteries.

Patients who have undergone rhinoplasty surgery concomitant with surgery in the septal region, might have had their blood supply compromised.

Reconstructive plastic or cosmetic surgery can greatly alter the vascularization of the nasal tip, nostrils, columella, and canine fossa, and it is possible that an embolization could affect the angular arteries. The manipulation of ethmoid arteries during surgical procedures increases the risk of occlusive vascular accidents.

The columella and lateral nasal branches irrigate the nasal ala, dorsum, and apex (tip). The lateral nasal veins are 2 or 3mm from nasal alar fold, and as the artery of the columella, arises deeply in the nasal base, ending at the tip, in the subdermal plexus. Fillings in this region—especially those used to sharpen, lengthen and minimize the nostril in an attempt to create a more Caucasian nasal profile for patients of African heritage—require lateral and deeper injections, as well as higher volumes, both conditions that increase the risk.

MALAR REGION (11)

It is an infrapalpebral triangular area, limited medially by the nasal region up to the lower portion of the nasolabial fold, and from that point, by an imaginary line up until the zygomatic arch. The analysis of this area must consider the anatomical details described for the nasociliary region and lacrimal nasojugal sulcus, since its correction is many times carried out concomitantly with the treatment of these other regions.

The malar region is nourished by branches of the angular artery (facial/external carotid) and by another that arises

through the infraorbital foramen (branch of the internal carotid artery), together with the vein and the sensory neural system of the infraorbital nerve. When a choice is made for retrograde injection, the planes and location for the product can be well controlled. On the other hand, the bolus injection technique, when performed in an intempestive manner, especially with an aim at reconstituting volume in the supraperiosteal region, can lead to obstruction of the infraorbital foramen, and damage of the vasculature, possibly even resulting in neural necrosis. In this region there is a thick layer of subcutaneous tissue and fat. The mid-subcutaneous plane—which marks the transition between its looser and its denser part—is characteristic of this region and makes the injection of fillers safe, because the important neural structures are located at deeper levels and the main vessels go along the lateral line of the nasal region.

ZYGOMATIC REGION (12)

As the nomenclature itself suggests, the zygomatic region is located laterally to the malar region, below the temporal region and anterior to the preauricular region. Its main structure is the zygomaticofacial nerve (branch of the trigeminal nerve) that emerges from the foramen located in the mid-lateral portion of the zygomatic bone. The considerations are similar to those related to the injection of fillers with consequent obstruction of the foramen. There is an important artery complex in deeper planes. The zygomatic palpebral vein is also located in this region and is most often visible with the stretching of the skin.

CANINE FOSSA (13) AND NASOLABIAL FOLDS (14)

With the current technique for volumetric repair of the malar region, the canine fossa region and the nasolabial sulcus have been filled less frequently and with smaller volumes, reducing the risks. Nonetheless, there are several reports of necrosis in this region, including the nasal ala, nasal dorsum, and part of the paranasal region. The two main causes of this complication are the embolization or compression of the artery due to the great amount of product injected and, possibly, intempestive technique. Anatomical variations are very common and must always be considered when analyzing the anatomy of the face. The main blood vessels are the angular arteries and part of the superior labial artery, which may also be compromised depending on the portion of the nasolabial fold where the filler is injected.

LOWER AND UPPER LIP (15 AND 16)

The arteries that irrigate the lips are the upper and lower lip arteries (branches of facial artery) that anastomose with those on the opposite side, forming an arterial circle around the rhyme of the mouth. The position of the arteries is unfavorable to the current techniques used to enhance the volume of and the convex shape of the lips. When performed on a superficial plane—in the skin, mucosa, or at the junction of the skin and mucosa—the lip contour injection brings few complications.

The labial arteries are curved and undulated, and therefore can be transfixed. In the anteroposterior view, they are loca-

ted in a posterior position to the orbicularis oris muscle, and are relatively superficial in the projection of the boundary between the wet and dry mucosae of the lips. This is the region of choice for many professionals to inject the filler when aiming at obtaining anterior projection and volume of the lips. Hematomas are frequent due to the absence of a firm tissue to contain arterial bleeding. As a result, compression of the vessel transfixed during the procedure must be firm and prolonged (three minutes or more). Cold compresses are useful.

Cheek (17)

Corresponds to a free, “loose”, and unfixed region that is located up to the 1cm point laterally to the angle of the mouth. It is inferior to the zygomatic region, anterior to the pre-auricular region, inferior to the pre-mandibular region (“pre-jowl”) and lateral to the malar region.

The arterial branches originate from the facial artery that runs into the lips and around the nasal region (angular artery), including part of the parotid duct, distributed in this region. The loss of volume is common in individuals who practice sports intensely and frequently, can be constitutional, can be caused by ingestion of drugs, or by consumptive diseases. It is often the only area that needs correction.

PRE-AURICULAR REGION (18)

It is an area posterolateral to the cheek border. It includes the zone that goes from a point 2cm anterior to the tragus muscle up until the same muscle. The superior limit is the zygomatic region, and the inferior limit is the zone of the mandibular angle 1.5 cm from the posterior mandibular border. In this region, in a point near the tragus, the facial nerve that innervates the various structures/regions of the face arises. There are deep vascular branches originating from the internal carotid artery, nevertheless the structure of greatest importance is the parotid gland, which lies under the subcutaneous tissue. Therefore, the filling of this region is carried out only in the skin and subcutaneous tissue. Between this region and the cheek, roughly one-third anterior to the angle of the mandible (between the anterior and posterior mandible), runs the path of the facial artery, which at this point is already branching and distributing into the perioral region, and a few others into the pre-tragus area.

LABIOMENTAL SULCUS (19)

The labiomentale sulcus comprises a band that covers the area between the lateral angle of the mouth up to a point 1cm lateral to it (the lateral angle of the mouth). It runs caudally up until the mandibular border. In addition to the arterial branches that supply the upper and lower lips, this region presents an important superficial venous vasculature, with large diameter vessels. This vasculature can often be seen when distending the skin of patients with thin skin and phototypes I or II. Often there is ecchymosis and, not infrequently, hematoma, due to the fact that this portion is free and there are no compartments or boundaries that may contain the bleeding. In this site, transfixed vessels must receive firm compression for a few minutes.

MENTONIAN REGION (20)

The mentonian region does not present risky structures, however the mental foramen may suffer inadvertent injection of filling substance with the compromise of the structures that run through this area. The localization of these structures is roughly made using the mid pupilar line—which is used to localize the main sensory foramina of the face. The arterial branch of the lower lip can be found in the labiomental sulcus region. The first crosses the region and venous system, which due to its proximity to the drainage system becomes more calibrous, with frequent presence of hematomas or ecchymoses.

POSTERIOR MANDIBULAR REGION (21)

The posterior mandibular region, situated between the anterior border of the masseter and the angle of the mandible, was delimited as a risk zone. Close to the anterior border of the masseter, in the mandibular bone, a depression can be found where the facial artery lies. This depression is created throughout a patient's life by the artery pulsating on the bone. Therefore, due to the fact that fillers are injected into the skin or subcutaneous tissue, they usually do not cause trauma to it. Nonetheless, aggressive procedures performed without anatomical knowledge, can result in serious arterial lesions.

ANTERIOR MANDIBULAR REGION (22)

This region is located 1cm posterior to the melolabial sulcus (as the labiomental region was delimited for didactic purposes) and the anterior border of the masseter, representing the region called “pre-jowl” or “bulldog”. This leaves free 1cm of the labiomental area, where fillers can be applied for the improvement of the facial contour. It does not present high risk structures, but in general filling procedures are not carried out in this area due to the fact that worsening of local sagging may occur, with the possibility of the weight of the filling substance causing a negative outcome when the objective is to obtain a rejuvenating facial contour.

CONCLUSION

Only a detailed knowledge of facial anatomy can allow the professional to carry out procedures safely. Correlating different areas with procedural risks can be useful for the physician when starting to work with fillers. It is important to note, however, that the present study does not suggest a new anatomical classification, but only a segregation of facial regions that are usually treated with cutaneous fillers in order to analyze them in isolation. ●

REFERENCES

- Goldberg DJ. With this filler/volumizing agent now becoming available, the interest in non-surgical facial sculpturing will continue to expand. *J Cosmet Laser Ther.* 2008;10(3):133.
- Alam M, Gladstone H, Kramer EM, Murphy JP Jr, Nouri K, Neuhaus IM, et al. ASDS guidelines of Care: injectable fillers. *Dermatol Surg.* 2008;34(Suppl 1):s115-s148.
- André P, Levy P. New trends in face rejuvenation by hyaluronic acid injections. *J Cosmetic Dermatol* 2008;8(4):251-258.
- Sadick NS, Karcher C, Palmisano L. Facial enhancements using dermal fillers. *Clin Dermatol.* 2009;27(3):s3-s12.
- Carruthers J, Cohen SR, Joseph JH, Narins RS, Rubin M. the science and art of dermal fillers for soft-tissue augmentation. *J Drugs Dermatol.* 2009;8(4):335-50.
- Kwon SG, Hong JW, Roh TS, Kim YS, Rah DK, Kim SS. Ischemic oculomotor nerve palsy and skin necrosis caused by vascular embolization. *Ann Plast Surg.* 2013;71(4):333-4.
- Omranifard M, Taheri S. Filler augmentation, safe or unsafe: A case series of severe complications of fillers. *J Res Med Sci.* 2011;16(12):1627-31.
- Park SW, Woo SJ, Park KH, Huh JW, Jung C, Kwon OK. Iatrogenic retinal artery occlusion caused by cosmetic facial filler injections. *Am J Ophthalmol.* 2012;154(4):653-62.
- Kim YJ, Choi KS. Bilateral blindness after filler injection. *Plast Reconstr Surg* 2013;131(2):298e-9e. d
- Glogau RG, Kane MAC. Effect of injection techniques on the rate of local adverse events in patients implanted with nonanimal hyaluronic acid gel dermal fillers. *Dermatol Surg.* 2008;34(Suppl 1):s105-09.
- Hirsch RJ, Stier M. Complications of soft tissue augmentation. *J Drugs Dermatol.* 2008;7(9):841-5.
- De Figueiredo JC, Naufal RR, Zampar AG, Mélega JM. Expanded median forehead flap and Abbé flap for nasal and upper lip reconstruction after complications of polymethylmethacrylate. *Aesth Plast Surg.* 2010; 34(3): 385-7.
- Altruda Filho L, Cândido PL, Larosa PRR, Cardoso EA. Anatomia topográfica da cabeça e do pescoço. Barueri (SP): Manole; 2005.
- Gardner E, Gray DJ, O´Rahilly R. Anatomia. 4 ed. Rio de Janeiro: Guanabara Koogan; 1978.
- Sobotta J, Becher H. Atlas de Anatomia Humana. 17 ed. Rio de Janeiro: Guanabara Koogan; 1977.
- Tamura B. Anatomia da face aplicada aos preenchedores e à toxina botulínica. Parte I. *Surg Cosmet Dermatol.* 2010 2(3):195-202.
- Tamura B. Anatomia da face aplicada aos preenchedores e à toxina botulínica. Parte II. *Surg Cosmet Dermatol* 2010 2(4):291-303.
- Haddock NT, Saadeh PB, Boutros S, Thorne CH. The tear trough and lid/cheek junction: anatomy and implications for surgical correction. *Plast Reconstr Surg.* 2009;123(4):1332-40; discussion 1341-2.